



ILEAL LYMPHOMA: PITFALLS OF PALPABLE MASS IN THE RIGHT ILIAC FOSSA

Andee Dzulkarnaen Zakaria^{1*}, Syed Hassan¹, Siti Aishah Zailani², Syed Azhar Syed Sulaiman², Amer Hayat Khan²

¹Department of Surgery, School of Medical Sciences, Universiti Sains Malaysia, Health Campus, Kelantan, Malaysia

²Department of Clinical Pharmacy, School of Pharmaceutical Sciences Universiti Sains Malaysia, 11800 Penang, Malaysia

*Corresponding Author Email: andee@kb.usm.my

DOI: 10.7897/2277-4572.031117

Published by Moksha Publishing House. Website www.mokshaph.com

All rights reserved.

Received on: 05/07/13 Revised on: 02/12/13 Accepted on: 05/01/14

ABSTRACT

In the gastrointestinal organ, the ileum is more frequently affected as compared to duodenum and jejunum. Studies showed that Non-Hodgkin Lymphoma of the ileum accounts for some 3 % of extra nodal onset lymphoma and 20 % of gastrointestinal lymphoma. Symptoms that commonly presence in Non Hodgkin lymphoma patients is fever, abdominal pain and weight loss. The right iliac fossa is predisposed to high tenderness because of anatomical and functional reasons. Differential diagnosis of palpable mass in lower right abdominal quadrant can sometimes be difficult. Surgery represents the elective treatment for primary forms, followed by chemotherapy and radiotherapy. Patients with ileal lymphoma usually underwent emergency intestinal resection. This is a case of post-operative surgery and medications given to this patient specifically to treat his complications after surgery.

Keywords: gastrointestinal lymphoma, chemotherapy, intestinal resection

INTRODUCTION

Lymphomas of the gastrointestinal tract are the most common type of primary extra nodal lymphomas, accounting for 5 to 10 % of all non-Hodgkin's lymphomas.^{1,2} Adult Non-Hodgkin lymphoma is a disease in which malignant (cancer) cells form in the lymph system. Risk factors that can affect the development of adult Non-Hodgkin lymphoma are age, gender and a weakened immune system. Possible signs of this disease include fever, sweating, fatigue and weight loss.³ Lymph node biopsy is a small operation used as a test examination to diagnose Non-Hodgkin's lymphoma in order to see if it contains non Hodgkin's lymphoma cells. If the cancer cells presence, an operation may be done. Operation for ileal lymphoma is usually by intestinal resection. The surgery can be performed through a traditional, open incision or using a laparoscopic technique. Enterocutaneous fistula (ECFs) is a complication that usually seen following surgery on the small or large bowel. In general surgical wards, ECFs are a common presentation and these lesions are responsible for a significant mortality rate, ranging from 5-20 % despite of advances in the management due to associated sepsis, nutritional abnormalities and electrolyte imbalances.⁴ Wound infection, bleeding and abscess at the site of operation also are some of the complications that associated with post-surgery.

Case Presentation

A 71-year-old-Malay man was admitted to the department of surgery in hospital university Sains Malaysia (HUSM) with palpable mass on the right iliac fossa that had developed due to ileal lymphoma which was confirmed by X-ray Computed tomography (CT scan) and ultrasound guided biopsy (Figure 1). The patient had a history of deep vein thrombosis on the right lower limb and he was on tablet warfarin. On admission, the patient complains of pain at the site of biopsy that was taken at the site of right iliac fossa. Erythematous skin changes were noted around the area but no changes in bowel habit. Besides, he also claimed that he had loss of appetite due to mouth ulcers and loss of weight was noted. Physical examination revealed on pale patient with blood

pressure 114/68 mmHg and lower heart rate of 54 beats/min. His body temperature is normal (37°C). Examination of eyes and ears all were normal but mouth examination showed multiple oral ulcers. His cardiovascular system showed regular rhythm and the pulse was good. A result from routine laboratory which is blood test indicates that the amount of red blood cell and hemoglobin were low but the amount of platelet was high. Chest x-ray was clear. Clinically the patient was suspected of having ileal lymphoma and to confirm this diagnose, the histopathological examination is going to review and since the patient is on tablet warfarin, INR/PT/aPTT blood taking for warfarin monitoring also will be done. Medication was instituted which is antibiotic prophylaxis in combination of Cefobid® 1 gram twice daily and Flagyl® 500 mg three times daily, both intravenously. Cefobid or Cefoperazone is third generation of cephalosporin that active in vitro against a wide range of aerobic and anaerobic, gram-positive and gram-negative pathogens whereas Flagyl or Metronidazole is bactericidal against anaerobic bacteria. Intestinal resection is a surgery procedure intended to remove all or part of an organ that contains cancer. The resection may include the small intestines and nearby organs in case the cancer has spreads. The section of the small intestine that contains cancer is removed and anastomosis is performed which mean joining the cut ends of the intestine together.

DISCUSSION

Ileal lymphoma is a rare disease that occurs among populations because only few cases were reported in the literature. Small bowel lymphomas are rare due to several reasons but recently, the incidence of the disease keep rising especially among immune-compromised patients and elderly. Ileal lymphoma disease may be associated with either B-cell lymphomas or T-cell lymphomas.⁹ Nevertheless, one of the particularities of my case is that medical history of my patient did not suggest any one of these syndromes whether the disease caused by B-cell or T-cell. Furthermore, results from histopathological examination still pending until my last day of follow-up.

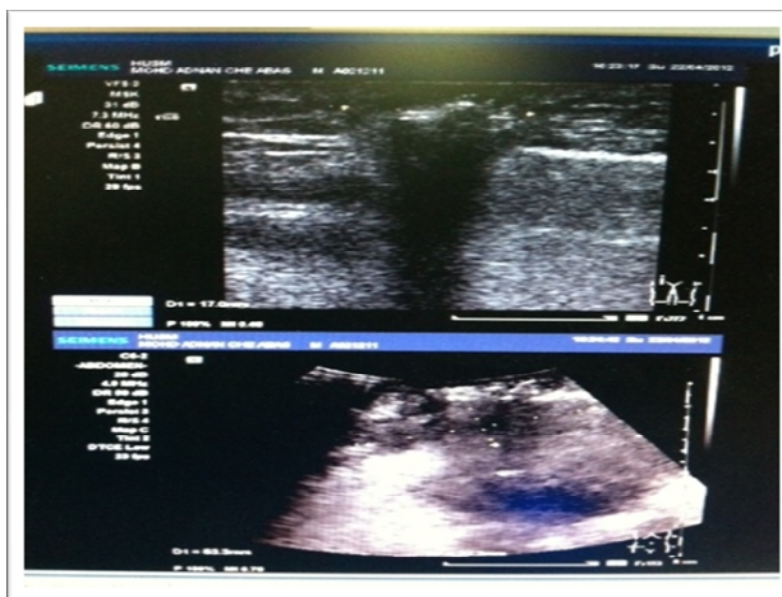

Figure 1: Ultrasonography

According to the surgeon in the surgical ward of HUSM, to obtain result from HPE, it may take at least one week. Histopathological examination important to indicate whether the removal of tumor is cleared or is there any residual cancer left behind. A wide range of clinical presentation can occurs for primary small bowel non-Hodgkin's lymphoma including non-specific abdominal pain, weight loss and fever. Abdominal palpable mass is found in only 15 % of cases which is the case of my patient; a palpable mass was found on the right iliac fossa. The presence of abdominal mass indicates the initial complications which can be the revealing mode of the small bowel lymphomas. Radiological diagnosis of ileal lymphoma can be suspected in computed tomography (CT scan) which shows the appearance of it is characteristic and ultrasonography (US) which can show a typical image of the lymphoma. These radiological diagnoses help physicians to obtain information regarding the obstructive syndrome, its mechanism, the presence of mass, its precise location and show it causes¹⁰. Upon admission, he had been started with IV Cloxacillin 1 g four times a day. Intravenous Cloxacillin was administered to this patient as a prophylaxis in order to prevent post-surgical wound infections⁵. Since the patient complains of oral ulcers, he was prescribed with oral gel which is Bonjela for local anesthetic and thymol gargle three times a day. Bonjela is clear, almost colorless gel, which is applied to the inside of the mouth or gums. It contains choline salicylate (a pain killer and anti-inflammatory) which soothes sore areas in the mouth and an antiseptic called cetalkonium chloride, which kills bacteria and helps prevent infection. Bonjela is intended for adults and children over 16 years old.⁶ The patient was on IV Tramadol 50 mg given four times a day for synthetic analgesic to treat moderate to severe pain.⁷ Initially, the dose for tablet warfarin given to the patient was 3.5 mg once daily. However, after INR monitoring, the level showed 1.74 which does not within the therapeutic range (2.0-3.0). Plan was make to increase the dose to 4.0 mg once daily and INR results showed that the INR was 2.09. He received regular infusion of normal saline 2 pints for 24 hours from the day he was administered

intravenously, normal saline supplying extra water to a dehydrated patient or supplying the daily water and salt needs of a patient who is unable to take them by mouth. As the day continue, the patient still tolerate minimally to oral intake. Thus, parenteral nutrition had been given to him. For the management of ileal lymphoma, the surgical approach is necessary. The main purpose of surgery is to remove mass or tumors that have high potency to spreads. Intestinal resection should be preferred if the stage of ileal lymphoma still not severe in order to limit the risk of serious complications such as perforation, bleeding and obstruction. In early stage-patients like this patient, complete resection surgery is more advantageous in some report.^{8,11} Complication after surgery such as enterocutaneous fistula usually can be seen due to surgery on the small and large bowel. Same problem also occurs to this patient whereby after several days of operation, patient has fecal discharge or abscess out from an opening at right iliac fossa mass which is different site from site of biopsy.⁴ Enterocutaneous fistulae are abnormal communications between the gastrointestinal tract and the skin. The complication may occur due to the underlying disease such as inflammatory bowel disease, appendicitis or duodenal ulcer. It has a significant mortality and morbidity as a result of associated sepsis, malnutrition and fluid imbalance. The conservative management of enterocutaneous fistulae is the protection of the surrounding skin from contact with the effluent¹². From the medications that being prescribed by the doctor to this patient, some of drug related problem are found. For example, Bonjela given to the patient to treat mouth ulcer contains choline salicylate and cetalkonium chloride. Salicylate may increase the effect of warfarin since the warfarin also administer together due to the DVT he is having. Bonjela is given only for one day. Flagyl or metronidazole also may potentiate the effect of warfarin results in prolongation of Prothrombin time and increase hemorrhagic risk caused by decrease in hepatic catabolism. Thus, patient should be more frequently monitored and anticoagulant therapy adjusted.


CONCLUSION

Although the information about clinical management of ileal lymphoma still not well documented in literature, however surgical is the most preferable method used by many physicians but in combination with chemotherapy.

REFERENCES

1. Vadala G, Salice M, Caragliano P and *et al.* Complications of ileal lymphoma. US National Library of Medicine 1995; 50(11): 963-6.
2. Zinzani PL, Magagnoli M, Pagliani G and *et al.* Primary intestinal lymphoma: Clinical and therapeutic features of 32 patients. Institute of Hematology and Oncology 1997; 82(3): 305-8.
3. Adult Non-Hodgkin Lymphoma Treatment. National Cancer Institute. <http://www.cancer.gov/cancertopics/pdq/treatment/adult-non-hodgkins/Patient/page1#Keypoint4>; 2012.
4. Vikram Kate. Enterocutaneous Fistula. <http://emedicine.medscape.com/article/1372132-overview>; 2011.
5. Melecia M, Antonio Velmonte. Cloxacillin in the treatment of *Staphylococcal* Infection: Reevaluation of after 15 years. *Phil J microbial Infection* 1985; 14(1): 19-22.
6. Bonjela. Choline Salicylate and Cetalkonium Chloride. [pamphlet]
7. Tramadol update. Medicine Update. [pamphlet]
8. Small intestine cancer. Gastrointestinal surgery. <http://gi.surgery.ucsf.edu/conditions--procedures/small-intestine-cancer.aspx>; 2012.
9. Karim Ibn Majdoub Hassani, Hicham El bouhaddouti, Abdelmalek Ousadden and *et al.* Non-Hodgkin's lymphoma revealed by ilio-colic intussusceptions in a Moroccan patient: a case report; 2010.
10. Ross GJ. Jejunojejunal intussusceptions secondary to a lipoma. *Radiol* 2000; 216: 727-30. <http://dx.doi.org/10.1148/radiology.216.3.r00se33727>
11. Ibrahim EM, Ezzat AA, Ei Weshi *et al.* Primary intestinal diffuse large B-cell non-Hodgkin's lymphoma: clinical features, management and prognosis of 66 patients. *Ann Oncology* 2001; 12: 53-58. <http://dx.doi.org/10.1023/A:1008389001990>
12. C Cro, KJ George, J Donnelly and *et al.* Vacuum assisted closure in management of enterocutaneous fistula 2002; 78: 364-365.

Source of support: Nil, Conflict of interest: None Declared

QUICK RESPONSE CODE 	ISSN (Online) : 2277-4572
	Website http://www.jpsonline.com

How to cite this article:

Andee Dzulkarnaen Zakaria, Syed Hassan, Siti Aishah Zailani, Syed Azhar Syed Sulaiman, Amer Hayat Khan. Ileal lymphoma: Pitfalls of palpable mass in the right iliac fossa. *J Pharm Sci Innov.* 2014;3(1):102-104 <http://dx.doi.org/10.7897/2277-4572.031117>